

Lapiplasty®

3-Plane Correction at the CORA

Publications Overview

Summary of 21 Peer-Reviewed Lapiplasty® Publications



The Leader in Advancing the Scientific Study of Hallux Valgus


PearlDiver Independent Survey

TREACE®
Medical Concepts, Inc.



Contents lists available at ScienceDirect

The Journal of Foot & Ankle Surgery

journal homepage: www.jfas.org

Original Research

One- and Two-Year Analysis of a Five-Year Prospective Multicenter Study Assessing Radiographic and Patient-Reported Outcomes Following Triplanar First Tarsometatarsal Arthrodesis With Early Weightbearing for Symptomatic Hallux Valgus

George T. Liu, DPM, FACFAS¹, Avneesh Chhabra, MD, MBA², Mindi J. Dayton, DPM, MHA, FACFAS³, Paul D. Dayton, DPM, MS, FACFAS³, William J. Duke, DPM, FACFAS⁴, Daniel C. Farber, MD⁵, Daniel J. Hatch, DPM, FACFAS⁶, Deidre A. Kile, MS⁷, Jennifer Koay, MD⁸, Jody P. McAleer, DPM, FACFAS⁴, Abdi Raissi, MD⁹, Katherine M. Raspovic, DPM, FACFAS¹, Robert D. Santrock, MD¹⁰, Robert P. Taylor, DPM, FACFAS¹¹, Michael D. VanPelt, DPM, FACFAS¹, Dane K. Wukich, MD¹²

¹ Associate Professor, Department of Orthopaedic Surgery, University of Texas Southwestern Medical Center, Dallas, TX

² Professor of Radiology & Orthopedic Surgery, Chief of Musculoskeletal Radiology, Department of Radiology, University of Texas Southwestern Medical Center, Dallas, TX

³ Foot and Ankle Center of Iowa/Midwest Bunion Center, Ankeny, IA

⁴ Jefferson City Medical Group, Jefferson City, MO

⁵ Associate Professor of Orthopaedic Surgery, Vice Chair for Education, University of Pennsylvania Medicine, Perelman School of Medicine, Philadelphia, PA

⁶ Foot and Ankle Center of the Rockies, Greeley, CO

⁷ Biostatistician, Evergreen, CO

⁸ Associate Professor of Radiology, West Virginia University, School of Medicine, Morgantown, WV

⁹ Desert Orthopaedic Center, Las Vegas, NV

¹⁰ Orthopedic Foot & Ankle Center, Worthington, OH

¹¹ Stonebriar Foot & Ankle, Frisco, TX

¹² Professor, Department of Orthopaedic Surgery, University of Texas Southwestern Medical Center, Dallas, TX

ARTICLE INFO

Level of Clinical Evidence: 4

Keywords:

bunionectomy
early weightbearing
lapisus bunionectomy
tripplanar first tarsometatarsal arthrodesis

ABSTRACT

We report one- and 2-year results of a prospective, 5-year, multicenter study of radiographic, clinical, and patient-reported outcomes following triplanar first tarsometatarsal arthrodesis with early weightbearing. One-hundred and seventeen patients were included with a mean (95% confidence interval [CI]) follow-up time of 16.6 (15.5, 17.7) months. Mean (95% CI) time to weightbearing in a boot walker was 7.8 (6.6, 9.1) days, mean time to return to athletic shoes was 45.0 (43.5, 46.6) days, and mean time to return to unrestricted activity was 121.0 (114.5, 127.5) days. There was a significant improvement in radiographic measures with a mean corrective change of -18.0° (-19.6° , -16.4°) for hallux valgus angle, -8.3° (-8.9° , -7.8°) for intermetatarsal angle and -2.9° (-3.2° , -2.7°) for tibial sesamoid position at 12 months ($n = 108$). Additionally, there was a significant improvement in patient-reported outcomes (Visual Analog Scale, Manchester-Oxford Foot Questionnaire, and Patient-Reported Outcomes Measurement Information System) and changes were maintained at 12 and 24 months postoperatively. There was 1/117 (0.9%) reported recurrence of hallux valgus at 12 months. There were 16/117 (13.7%) subjects who experienced clinical complications of which 10/117 (8.5%) were related to hardware. Of the 7/117 (6.0%) who underwent reoperation, only 1/117 (0.9%) underwent surgery for a non-union. The results of the interim report of this prospective, multicenter study demonstrate favorable clinical

Financial Disclosure: G.T. Liu is a consultant for Orthofix and Gramercy Extremity Orthopedics. A. Chhabra is a consultant for Image Biopsy Labs and Icon Medical. K.M. Raspovic is a consultant for Orthofix. D.K. Wukich is a consultant for Orthofix and Wright Medical Technology and receives royalties from Arthrex.

Conflict of Interest: A. Chhabra, W.J. Duke, D.C. Farber, D.J. Hatch, J.P. McAleer, M.J. Dayton, P.D. Dayton, A. Raissi, R.D. Santrock, R.P. Taylor and J. Koay are consultants for Treace Medical Concepts, Inc. W.J. Duke, D.J. Hatch, J.P. McAleer, M.J. Dayton, P.D. Dayton

and R.D. Santrock have open market stock ownership of Treace Medical Concepts, Inc. P.D. Dayton, D.J. Hatch, J.P. McAleer and R.D. Santrock receive royalties for intellectual property from the Treace Medical Concepts, Inc.

Address correspondence to: George T. Liu, DPM, FACFAS, Department of Orthopaedic Surgery, University of Texas Southwestern Medical Center, 1801 Inwood Road, Dallas, TX 75390
E-mail address: George.liu@utsouthwestern.edu (G.T. Liu).

Study Summary

Interim analysis from the Lapiplasty® ALIGN3D™ multicenter, prospective clinical study of 117 patients with at least 12 months of follow-up, of whom 40 patients have at least 24 months of follow-up (out of 173 total study patients).

- Early return to weight bearing in a walking boot within 7.8 days on average.
- Significant improvement in radiographic measures of 3-dimensional bunion correction from pre-surgery to 6 weeks and maintained at 12 months (n=108) and 24 months (n=38) post-surgery; with 1 recurrence reported at 12 months post-surgery (0.9% recurrence rate).
- Return to work within 4 weeks (25.2 days) and to full, unrestricted activity within 4 months post-surgery on average.
- Significant improvement in patient-reported pain reduction on VAS (n=112) and quality of life measurements on MOxFAQ (n=113) and PROMIS (n=108) scores at 12 months and at 24 months (n=40).

Radiographic Results

Table 4

Radiographic measures at times: baseline, 6 week, 6 month, 12 months, 24 months, mean (95% CI)

Radiographic Measure	Baseline (n = 117)	6 Weeks (n = 115)	6 Months (n = 114)	12 Months (n = 108)	24 Months (n = 38)
Hallux valgus angle (HVA)	25.2° (24.0, 26.5)	8.6° (7.7, 9.5)	6.8° (5.7, 7.9)	7.1° (6.0, 8.3)	7.2° (5.2, 9.1)
Intermetatarsal angle (IMA)	13.1° (12.6, 13.7)	4.0° (3.6, 4.4)	4.7° (4.3, 5.1)	4.8° (4.3, 5.2)	5.0° (4.1, 5.9)
Tibial sesamoid position (TSP)	5.2 (5.0, 5.4)	1.6 (1.4, 1.7)	2.0 (1.8, 2.2)	2.3 (2.0, 2.5)	2.1 (1.7, 2.4)
Sagittal plane intermetatarsal angle*	1.4° (1.1, 1.8)	0.6° (-0.0, 1.2)	0.3° (-0.2, 0.8)	-0.1° (-0.7, 0.4)	1.4° (-0.5, 3.3)

Abbreviation: CI, confidence interval.

* Dorsiflexion is a positive value.

Table 6

Patient-reported outcomes, mean (95% CI)

Measure	Baseline	6 Months	12 Months	24 Months	Change From Baseline		
					6 Months	12 Months	24 Months
VAS pain score	n = 117 4.7 (4.4, 5.0)	n = 114 1.3 (1.0, 1.6)	n = 112 1.0 (0.8, 1.2)	n = 40 0.8 (0.6, 1.1)	n = 114 -3.4 (-3.8, -3.0)	n = 112 -3.7 (-4.1, -3.3)	n = 40 -4.6 (-5.3, -3.9)
MOxFAQ walking/standing	n = 116 46.8 (42.6, 51.1)	n = 114 17.8 (13.8, 21.8)	n = 113 11.6 (8.4, 14.8)	n = 40 6.0 (3.3, 8.6)	n = 113 -29.7 (-35.0, -24.4)	n = 112 -35.6 (-40.4, -30.7)	n = 40 -45.8 (-52.6, -39.0)
MOxFAQ pain	n = 117 56.2 (52.3, 60.0)	n = 114 22.8 (19.3, 26.4)	n = 113 19.2 (15.5, 23.0)	n = 40 11.6 (8.0, 15.3)	n = 114 -33.4 (-37.5, -29.3)	n = 113 -36.5 (-40.8, -32.1)	n = 40 -49.5 (-56.4, -42.6)
MOxFAQ social interaction	n = 117 45.3 (41.1, 49.5)	n = 114 13.2 (9.5, 16.9)	n = 113 8.7 (5.6, 11.8)	n = 40 5.8 (2.3, 9.2)	n = 114 -32.2 (-36.9, -27.5)	n = 113 -35.8 (-40.3, -31.3)	n = 40 -47.3 (-53.4, -41.3)

Abbreviations: CI, confidence interval; VAS, visual analog scale; MOxFAQ, Manchester-Oxford Foot Questionnaire.

Table 7

. PROMIS-29, mean (95% CI)

Measure (PROMIS Domain)	Baseline (n = 110)	6 Months (n = 109)	12 Months (n = 108)	24 Months (n = 40)	Change From Baseline		
					6 Months (n = 107)	12 Months (n = 106)	24 Months (n = 40)
Physical function	45.5 (43.9, 47.0)	51.6 (50.2, 53.0)	54.0 (52.9, 55.1)	55.9 (55.0, 56.8)	6.1 (4.1, 8.0)	8.4 (6.5, 10.2)	11.2 (8.6, 13.8)
Anxiety	47.1 (45.5, 48.6)	43.7 (42.5, 44.9)	42.9 (41.8, 44.0)	43.8 (41.9, 45.7)	-3.4 (-5.0, -1.8)	-3.9 (-5.3, -2.5)	-3.2 (-5.2, -1.1)
Depression	43.5 (42.5, 44.6)	42.6 (41.8, 43.4)	42.2 (41.4, 43.0)	41.9 (40.6, 43.1)	-1.2 (-2.3, 0.0)	-1.3 (-2.5, -0.1)	-2.4 (-4.1, -0.6)
Ability to participate in social roles/activities	53.3 (51.6, 54.9)	60.0 (58.6, 61.4)	60.6 (59.3, 62.0)	62.2 (60.6, 63.7)	6.8 (5.0, 8.7)	7.0 (5.1, 8.9)	10.4 (7.7, 13.1)
Fatigue	45.5 (43.7, 47.2)	40.9 (39.4, 42.4)	40.4 (39.1, 41.8)	41.3 (38.9, 43.7)	-4.8 (-6.6, -3.0)	-4.5 (-6.3, -2.8)	-6.2 (-9.0, -3.4)
Pain interference	56.0 (54.6, 57.4)	47.1 (45.7, 48.5)	45.2 (44.0, 46.4)	43.2 (42.1, 44.4)	-8.8 (-10.6, -7.0)	-10.6 (-12.3, -8.9)	-13.4 (-16.1, -10.7)
Sleep disturbance	47.7 (46.3, 49.1)	44.5 (43.1, 46.0)	44.6 (43.2, 46.0)	43.2 (40.8, 45.6)	-3.2 (-4.8, -1.7)	-3.1 (-4.8, -1.4)	-4.1 (-6.8, -1.4)
Pain intensity	4.5 (4.1, 4.9)	1.3 (1.0, 1.6)	1.0 (0.7, 1.3)	0.6 (0.3, 0.9)	-3.3 (-3.7, -2.8)	-3.5 (-3.9, -3.1)	-4.3 (-5.0, -3.6)

Abbreviations: PROMIS-29, Patient-Reported Outcomes Measurement Information System, profile form 29, version 2.1; CI, confidence interval.

Study Conclusion

"We report statistically significant improvements in radiographic correction, low recurrence of deformity, and early return to activity with low complication rates up to a 24-month postoperative review. Additionally, we report statistical improvements in patients' health-related quality of life up to a 24-month follow-up period."

Multicenter Early Radiographic Outcomes of Triplanar Tarsometatarsal Arthrodesis With Early Weightbearing

Foot & Ankle International®
1–6
© The Author(s) 2019
Article reuse guidelines:
sagepub.com/journals-permissions
DOI: 10.1177/1071100719847700
journals.sagepub.com/home/fai

Justin J. Ray, MD¹, Jennifer Koay, MD², Paul D. Dayton, DPM, MS³,
Daniel J. Hatch, DPM⁴, Bret Smith, DO, MS⁵, and Robert D. Santrock, MD¹

Abstract

Background: Hallux valgus is a multiplanar deformity of the first ray. Traditional correction methods prioritize the transverse plane, a potential factor resulting in high recurrence rates. Triplanar first tarsometatarsal (TMT) arthrodesis uses a multiplanar approach to correct hallux valgus in all 3 anatomical planes at the apex of the deformity. The purpose of this study was to investigate early radiographic outcomes and complications of triplanar first TMT arthrodesis with early weightbearing.

Methods: Radiographs and charts were retrospectively reviewed for 57 patients (62 feet) aged 39.7 ± 18.9 years undergoing triplanar first TMT arthrodesis at 4 institutions between 2015 and 2017. Patients were allowed early full weightbearing in a boot walker. Postoperative radiographs were compared with preoperative radiographs for hallux valgus angle (HVA), intermetatarsal angle (IMA), tibial sesamoid position (TSP), and lateral round sign. Any complications were recorded.

Results: Radiographic results demonstrated significant improvements in IMA (13.6 ± 2.7 degrees to 6.6 ± 1.9 degrees), HVA (24.2 ± 9.3 degrees to 9.7 ± 5.1 degrees), and TSP (5.0 ± 1.3 to 1.9 ± 0.9) from preoperative to final follow-up ($P < .001$). Lateral round sign was present in 2 of 62 feet (3.2%) at final follow-up compared with 52 of 62 feet (83.9%) preoperatively. At final follow-up, recurrence was 3.2% (2/62 feet), and the symptomatic nonunion rate was 1.6% (1/62 feet). Two patients required hardware removal, and 2 patients required additional Akin osteotomy.

Conclusion: Early radiographic outcomes of triplanar first TMT arthrodesis with early weightbearing were promising with low recurrence rates and maintenance of correction.

Level of Evidence: Level IV, retrospective case series.

Keywords: hallux valgus, modified Lapidus, tarsometatarsal arthrodesis, bunion, triplanar

Introduction

Hallux valgus is a complex deformity of the first ray. Traditional correction methods for hallux valgus prioritize correction in the transverse plane based on anteroposterior (AP) radiographs. In particular, traditional methods of correction primarily target improvement of the hallux valgus angle (HVA) and intermetatarsal angle (IMA). Both the severity of the deformity and the method of operative correction have been largely based on this 2-dimensional representation, resulting in variable outcomes and some studies reporting high long-term recurrence rates ranging from 15% to 78% with these traditional approaches.^{1,3,7,8,19}

Recent evidence suggests that hallux valgus is a multiplanar deformity with significant contributions from the frontal and sagittal planes.^{3,10,11} With the addition of weightbearing computed tomography (CT) scans, the 3-dimensional nature

of hallux valgus is better characterized. Recent studies utilizing weightbearing CT scans have shown that patients with hallux valgus have abnormal first metatarsal pronation, greater 3-dimensional displacement at the first TMT joint,

¹Department of Orthopaedics, West Virginia University, Morgantown, WV, USA

²Department of Radiology, West Virginia University, Morgantown, WV, USA

³Foot & Ankle Center of Iowa, Ankeny, IA, USA

⁴Department of Podiatric Medicine and Surgery, North Colorado PMS Residency, Greeley, CO, USA

⁵Orthopedics, University of South Carolina, Palmetto Health-USC Orthopedic Center, Lexington, SC, USA

Corresponding Author:

Justin J. Ray, MD, Department of Orthopaedics, West Virginia University, P.O. Box 9196, Morgantown, WV 26506-9196, USA.
Email: justin.ray1@hsc.wvu.edu

Study Summary

- Multicenter retrospective review of 62 feet with average follow-up of 13.5 months
- 3-plane TMT arthrodesis with Lapiplasty® System and weight-bearing in a surgical boot at average 10.9 days
- 96.8% patients maintained their 3-plane correction (IMA, HVA, TSP); 2 feet with recurrence (3.2%)
- 1.6% patients experienced symptomatic nonunion

Radiographic Results

	Preop, n (%)	6 Weeks Postop, n (%)	4 Months Postop, n (%)	12 Months Postop, n (%)	P Value
IMA	13.6 ± 2.7	6.1 ± 2.1	6.1 ± 2.3	6.6 ± 1.9	<.001
HVA	24.2 ± 9.3	11.6 ± 5.1	10.2 ± 5.9	9.7 ± 5.1	<.001
TSP	5.0 ± 1.3	1.6 ± 0.7	1.8 ± 0.9	1.9 ± 0.9	<.001

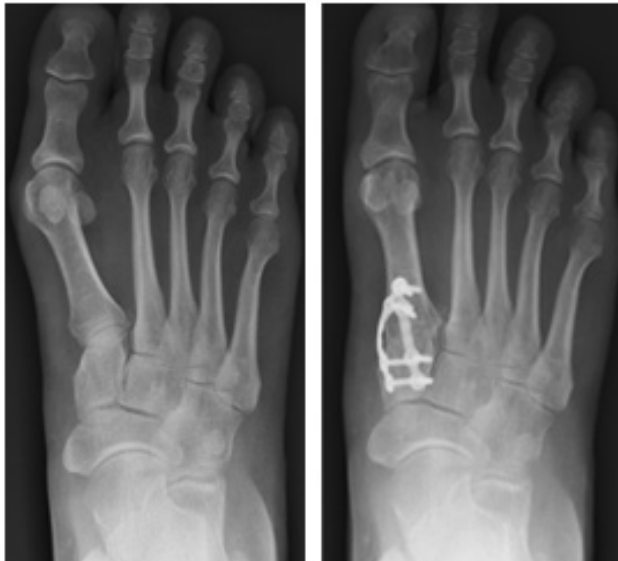Abbreviations: IMA - Intermetatarsal Angle; HVA - Hallux Valgus Angle; TSP - Tibial Sesamoid Position

Recurrence Measurements

	6 Weeks Postop, n (%)	4 Months Postop, n (%)	12 Months Postop, n (%)
HVA > 20 degrees	3/62 (4.8%)	4/62 (6.4%)	2/62 (3.2%)
Loss of correction > 50% (IMA, HVA, or TSP)	2/62 (3.2%)	2/62 (3.2%)	2/62 (3.2%)

Abbreviations: IMA - Intermetatarsal Angle; HVA - Hallux Valgus Angle; TSP - Tibial Sesamoid Position

Case Example from Publication



Study Conclusion


“Triplanar TMT arthrodesis resulted in significant improvements in IMA, HVA, and TSP at final follow-up with low recurrence rates. Patients tolerated early weight-bearing and early return to normal athletic shoes with minimal complications.”



Contents lists available at ScienceDirect

The Journal of Foot & Ankle Surgery

journal homepage: www.jfas.org



Comparison of Radiographic Measurements Before and After Triplane Tarsometatarsal Arthrodesis for Hallux Valgus

Paul Dayton, DPM, MS, FACFAS¹, Stefany Carvalho, BS², Rachel Egdorf, DPM³,
Mindi Dayton, DPM, MHA, FACFAS¹

¹ Surgeon, Foot & Ankle Center of Iowa/Midwest Bunion Center, Ankeny, IA

² Student, Des Moines University College of Podiatric Medicine and Surgery, Des Moines, IA

³ Resident, AMITA Saint Joseph Hospital Chicago, Chicago, IL

ARTICLE INFO

Level of Clinical Evidence: 4

Keywords:
bunion surgery
deformity apex
frontal plane
recurrence
rotation

ABSTRACT

We present a comparison of preoperative and final postoperative first ray measurements in 109 feet after triplane tarsometatarsal arthrodesis at a mean follow-up time of 17.4 months. Preoperative and final postoperative first ray variables including intermetatarsal angle (IMA), hallux valgus angle (HVA), tibial sesamoid position (TSP), distal metatarsal articular angle (DMAA), Seiberg index, metatarsal rotation angle (MRA), sesamoid subluxation, osseous union, and hardware failure were evaluated. Measurements were made by consistently using the mid-diaphyseal line of the bone segments for both preoperative and postoperative assessments. The mean preoperative HVA, IMA, and TSP were 22.9°, 13.3°, and 4.6°. The mean differences (95% confidence interval) in preoperative and postoperative values were −14.9° (−16.3° to −13.4°) for HVA, −7.7° (−8.2° to −7.2°) for IMA, and −2.6° (−2.8° to −2.3°) for TSP. Among bunions with MRA measurements, the mean difference was −12.3° (−14.5° to −10.0°). The preoperative to postoperative DMAA decreased by a mean of −14.2° (−15.9° to −12.6°). The results of this study suggest that triplane tarsometatarsal arthrodesis produces appropriate correction of hallux valgus radiographic parameters.

© 2019 by the American College of Foot and Ankle Surgeons. All rights reserved.

Algorithms for selecting a hallux abducto valgus (HAV) procedure rely primarily on 2-dimensional (2D) measurements such as intermetatarsal angle (IMA), hallux valgus angle (HVA), tibial sesamoid position (TSP), and distal metatarsal articular angle (DMAA) measurements (and therefore are 2D). Based on these measurements, it is not surprising that HAV correction is most commonly surgically addressed as a biplanar deformity, with angular and sliding osteotomies and capsular balancing procedures attempting only to correct transverse and sagittal plane angular deformities. This biplane thought process has resulted in recurrence rates as high as 73%, along with other complications, which may be due to failure to correct all 3 planes of the deformity (1).

Surgeons have complicated the topic of HAV and introduced bias in study results by using dual measurements to assess pre- and postoperative IMA (2). The anatomic IMA (aIMA) is the bisection of the mid-diaphyseal osseous segments of metatarsals 1 and 2. The mechanical

IMA is the line connecting the midpoint of the tarsometatarsal joint (TMT) and metatarsophalangeal joint (MTPJ) articular surfaces. When using the aIMA before surgery and the mechanical IMA after surgery, which is commonly taught, observation bias occurs. This practice overestimates correction of all of the angular measurements defining HAV deformity (3). Because osteotomy creates a deformity in a normally straight metatarsal, these angular measurements are not valid postoperatively. We believe this practice prevents accurate understanding of the outcomes of the dozens of osteotomy procedures described for bunion correction and prevents the development of best-practice protocols.

In contrast to the more traditional 2D osteotomy approach for bunion correction, the foot and ankle community has seen a renewed interest in the study of the 3D anatomy of the HAV deformity and the application of triplane corrective procedures. Relatively few clinical studies exist reporting the results of the 3D concept for correction. This study is a retrospective analysis of radiographs from a group of patients with HAV who underwent triplane TMT correction. Objectives of this study include comparison of preoperative and final postoperative first ray measurements including IMA, HVA, TSP, DMAA, Seiberg index (SI), lateral round sign (LRS), metatarsal rotation angle (MRA), sesamoid subluxation, osseous union, and hardware failure using a uniform anatomic measurement technique based on the mid-diaphyseal line of the bone segments for both preoperative and postoperative assessments.

Financial Disclosure: None reported.

Conflict of Interest: P.D. has been performing triplane TMT arthrodesis exclusively for nondegenerative bunions since 2009. He has worked as a consultant and design team surgeon with Treace Medical Concepts, Inc., since 2014. The other authors declare no conflicts of interest.

Address correspondence to: Paul Dayton, DPM, Foot & Ankle Center of Iowa/Midwest Bunion Center, 3720 N. Ankeny Blvd, Suite 103 Ankeny IA 50023.

E-mail address: daytonp@icloud.com (P. Dayton).

Study Summary

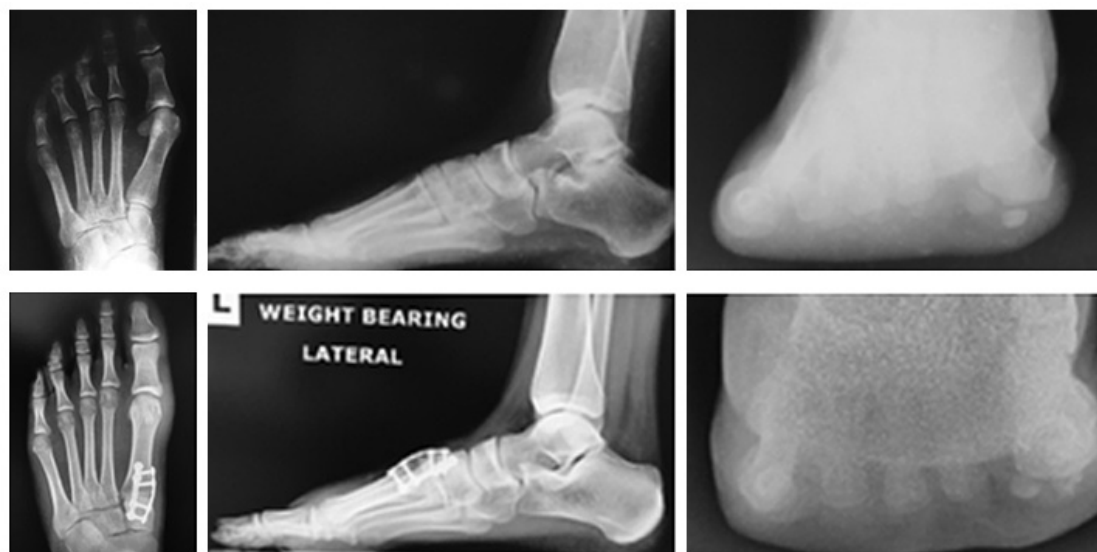
- Retrospective review of 109 feet with average follow-up of 17.4 months
- 3-plane TMT arthrodesis with Biplanar™ Plating and weight-bearing in a surgical boot within first week
- 99.1% patients maintained their 3-plane correction (IMA, HVA, TSP); 1 foot with recurrence (0.9%)
- 100% patients achieved bony fusion with 0% hardware failure

Radiographic Results

Variable	n	Mean	Standard Deviation	95% Confidence Interval
HVA				
Preoperative	109	22.9	7.6	21.4 to 24.3
Postoperative	109	8.0	4.5	7.1 to 8.9
Change	109	-14.9	7.4	-16.3 to -13.4
IMA				
Preoperative	109	13.3	2.4	12.9 to 13.8
Postoperative	109	5.7	2.4	5.2 to 6.1
Change	109	-7.7	2.7	-8.2 to -7.2
TSP				
Preoperative	109	4.6	1.2	4.4 to 4.9
Postoperative	109	2.0	0.8	1.9 to 2.2
Change	109	-2.6	1.3	-2.8 to -2.3
MRA				
Preoperative	92	7.8	8.0	6.0 to 9.7
Postoperative	77	-4.5	6.8	-5.9 to -3.1
Change	72	-12.3	9.5	-14.5 to -10.0
DMAA				
Preoperative	109	19.6	9.2	17.8 to 21.3
Postoperative	109	5.3	3.8	4.6 to 6.1
Change	109	-14.2	8.7	-15.9 to -12.6

Abbreviations: HVA - Hallux Valgus Angle; IMA - Intermetatarsal Angle; TSP - Tibial Sesamoid Position; MRA - Metatarsal Roation Angle (Frontal Plane); DMAA - Distal Metatarsal Articular Angle

Case Example from Publication 18 months post-op



Study Conclusion


"Triplane arthrodesis provides patients with robust and reliable correction of all planar components of the deformity, with low recurrence and low rate of healing problems at a mean of 17 months postoperatively."



Contents lists available at ScienceDirect

The Journal of Foot & Ankle Surgery

journal homepage: www.jfas.org



Comparison of the Mechanical Characteristics of a Universal Small Biplane Plating Technique Without Compression Screw and Single Anatomic Plate With Compression Screw

Paul Dayton, DPM, MS, FACFAS¹, Joe Ferguson, MS², Daniel Hatch, DPM, FACFAS³, Robert Santrock, MD⁴, Sean Scanlan, PhD², Bret Smith, DO⁵

¹ UnityPoint Clinic; and Assistant Professor, Des Moines University College of Podiatric Medicine and Surgery, Fort Dodge, IA

² Treace Medical Concepts, Inc., Ponte Vedra Beach, FL

³ Surgical Director, Northern Colorado Podiatric Medicine and Surgery Residency, Greeley, CO

⁴ Chief, Department of Foot and Ankle Surgery, West Virginia School of Medicine, Morgan Town, WV

⁵ Director, Foot and Ankle Division, Moore Center for Orthopedics, Lexington, SC

ARTICLE INFO

Level of Clinical Evidence: 5

Keywords:

arthrodesis
internal fixation
Lapidus
multiplane
twin plate

ABSTRACT

To better understand the mechanical characteristics of biplane locked plating in small bone fixation, the present study compared the stability under cyclic cantilever loading of a 2-plate locked biplane (BPP) construct without interfragmentary compression with that of a single-plate locked construct with an additional interfragmentary screw (SPS) using surrogate bone models simulating Lapidus arthrodesis. In static ultimate plantar bending, the BPP construct failed at significantly greater load than did the SPS construct (556.2 ± 37.1 N versus 241.6 ± 6.3 N, $p = .007$). For cyclic failure testing in plantar bending at a 180-N starting load, the BPP construct failed at a significantly greater number of cycles ($158,322 \pm 50,609$ versus $13,718 \pm 10,471$ cycles) and failure load (242.5 ± 25.0 N versus 180.0 ± 0.0 N) than the SPS construct ($p = .002$). For cyclic failure testing in plantar bending at a 120-N starting load, the results were not significantly different between the BPP and SPS constructs for the number of cycles ($207,646 \pm 45,253$ versus $159,334 \pm 69,430$) or failure load (205.0 ± 22.4 N versus 185.0 ± 33.5 N; $p = .300$). For cyclic testing with 90° offset loading (i.e., medial to lateral bending) at a 120-N starting load, all 5 BPP constructs (tension side) and 2 of the 5 SPS constructs reached 250,000 cycles without failure. Overall, the present study found the BPP construct to have superior or equivalent stability in multiplanar orientations of force application in both static and fatigue testing. Thus, the concept of biplane locked plating, using 2 low profile plates and uncortical screw insertion, shows promise in small bone fixation, because it provides consistent stability in multiplanar orientations, making it universally adaptable to many clinical situations.

© 2016 by the American College of Foot and Ankle Surgeons. All rights reserved.

Financial Disclosure: Paul Dayton has a consultant/advisory role with Treace Medical Concepts, Inc. (a company that markets the LapiPlasty™ Triplanar Deformity Correction system), receives honoraria from Biomet and Zimmer, and receives research funding from Des Moines University. Sean Scanlan owns stock in Treace Medical Concepts, Inc. Joe Ferguson is employed by Treace Medical Concepts, which financially supported this study. Daniel Hatch is a consultant for and has equity interest in Treace Medical Concepts, Inc. Robert Santrock is a paid consultant for Wright Medical Technology, Treace Medical Concepts, and Amnio Medical; is an owner of/receives royalties from Epic Extremity; and receives royalties from Treace Medical Concepts, Inc. Bret Smith has a consultant/advisory roll with Treace Medical Concepts, Inc. and receives honoraria from Smith/Nephew, Osteomed, and Mimedex.

Conflict of Interest: Treace Medical Concepts, Inc. (Ponte Vedra Beach, FL) funded the mechanical testing; engineering reports from the mechanical tests, which were conducted at an independent firm, are available for review.

Address correspondence to: Paul Dayton, DPM, MS, FACFAS, UnityPoint Clinic, Des Moines University College of Podiatric Medicine and Surgery, 804 Kenyon Road, Suite 310, Fort Dodge, IA 50501.

E-mail address: daytonp@me.com (P. Dayton).

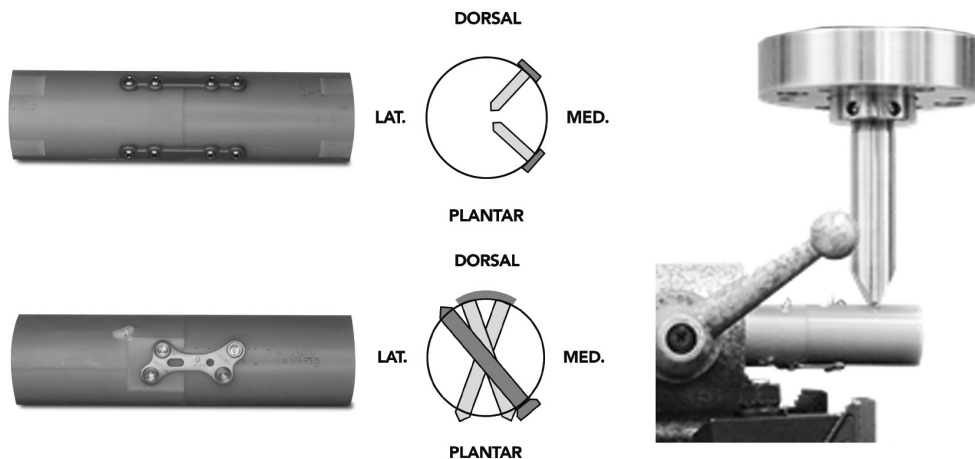
Osteosynthesis is a vital component of orthopedics for both trauma and reconstruction. The mechanical characteristics of orthopedic fixation influence bone healing by a complex cascade of biologic events. The biologic response of the bone varies depending on the design of the fixator (size, material, stiffness) and the forces placed across the fracture or osteotomy. Knowledge of the biologic effects that external mechanical forces induce in bone has led to new paradigms in fracture and osteotomy fixation. We can see from the published data that the success with many of the new techniques is still not fully understood. With our understanding of how the biology of bone healing is influenced by both fixed angle plates and traditional compression fixation, new recommendations for implants are emerging.

Construct stability can be achieved in several ways using fixed angle plates. Monolateral plate application along the axis of the bone requires the plate to have sufficient stiffness to resist the multiplane bending, traction, and rotational forces commonly experienced

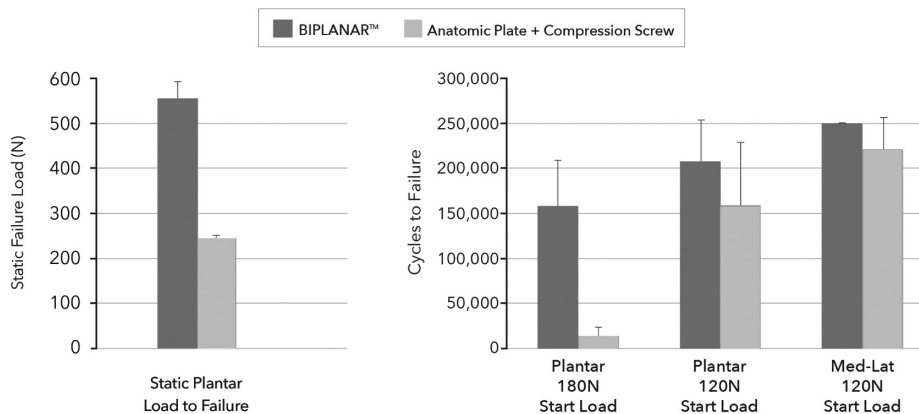
Study Summary

- Biomechanical testing of Biplanar™ Plating (Gen 1) versus dorsal Lapidus plate + 4.0mm interfrag screw
- Cantilever static and cyclic bending loading simulating Lapidus arthrodesis in surrogate bone models
- Biplanar™ Plating demonstrated greater biomechanical performance:
 - Static ultimate failure load: 556N vs 242N (130% increase)
 - Cycles to failure @180N start load: 158,322 vs 13,718 cycles (1,154% increase)

Biomechanical Test Setup



Static and Cyclic Biomechanical Results



Study Conclusion

"The results of the study demonstrated that a small Biplanar™ Plating construct without compression screw has superior or equivalent mechanical stability to a single anatomic plate with interfragmentary compression screw under both static and dynamic fatigue conditions."



Analysis of Shortening and Elevation of the First Ray With Instrumented Triplane First Tarsometatarsal Arthrodesis

Hatch D, Dayton P, DeCarbo W, McAleer J, Ray J, Santrock R, Smith B.
Foot & Ankle Orthopaedics 2020, 5(4): 1-8.


Summary: A prospective, multicenter study of 35 patients analyzing shortening and elevation of the first ray after instrumented triplane tarsometatarsal (TMT) fusion with the Lapiplasty® Procedure. At an average follow-up of 6-months, the results demonstrated a mean first ray shortening on sagittal and AP radiographs of 2.4 and 3.1mm, respectively. There was no increase in metatarsal elevation and no patients reported lesser metatarsal pain post-operatively.



Triplane Hallux Abducto Valgus Classification

Hatch DJ, Santrock RD, Smith B, Dayton P, Weil L Jr.
J Foot Ankle Surg. 2018, 57:972-981.


Summary: Rather than the 2D hallux valgus classification systems traditionally referenced, this manuscript presents a novel 3-plane (3D) classification system for the evaluation and procedure selection for hallux valgus treatment.
Class 1 - No metatarsal rotation; Class 2A - Metatarsal rotation without sesamoid subluxation; Class 2B - Metatarsal rotation with sesamoid subluxation; Class 3 - Metatarsus adductus bunion; Class 4 - Degenerative (DJD) bunion.



Progression of Healing on Serial Radiographs Following First Ray Arthrodesis in the Foot Using a Biplanar Plating Technique Without Compression

Dayton P, Santrock R, Kauwe M, Gansen G.
Harper S, Cifaldi A, Egdorf R, Eisenschink JJ.
J Foot Ankle Surg. 2019 May;58(3):427-433.

Summary: Multicenter, retrospective study of bone healing with accelerated weightbearing protocol in patients undergoing TMT or MTP fusions with Lapiplasty® biplanar plating. 195 patients were included with mean follow up of 9.5 months. Patients were allowed to begin weightbearing on the operative foot approximately at post-op day 5. 97.4% of patients demonstrated successful bony fusion and 98.9% maintained a stable joint position over the course of the study.



Comparison of Tibial Sesamoid Position on Anteroposterior and Axial Radiographs Before and After Triplane Tarsal Metatarsal Joint Arthrodesis

Dayton P, Feilmeier M.
J Foot Ankle Surg. 2017, 56:1041-1046.


Summary: Clinical study of 21 feet at 5.2 month average follow-up demonstrating the ability of the Lapiplasty® Procedure to successfully correct the three-dimensional (3D) deformity (including metatarsal frontal-plane rotation) in 95.2% of cases, and also restore the intermetatarsal angle to 5.5°, hallux valgus angle to 7.3°, and tibial sesamoid position to 1.8.



Effect on Foot Width With Triplanar Tarsometatarsal Arthrodesis for Hallux Valgus

Vaida J, Ray J, Shackleford T, Decarbo W, Hatch D, Dayton P, McAleer J, Smith B, Santrock R.
Foot & Ankle Orthopaedics 2020, 5(3): 1-5.


Summary: Multicenter, retrospective study of 144 patients (148 feet) who underwent the Lapiplasty® Procedure. All patients demonstrated a decrease in bony and soft tissue width after surgery. Bony width decreased by 10.4 mm (10.8%) postoperatively, whereas soft tissue width decreased 7.3mm (6.8%) postoperatively after triplanar first TMT arthrodesis.



Hallux Valgus Deformity and Treatment. A Three-Dimensional Approach: Modified Technique for Lapidus Procedure

Santrock RD, Smith B.
Foot Ankle Clin. 2018, 23:281-295.

Summary: Manuscript reviews the 3-plane hallux valgus classification system, the novel surgical steps of the Lapiplasty® Procedure, the Lapiplasty® Biplanar™ Plating biomechanical results, and presents clinical outcome data from a 49-patient multicenter study demonstrating 96% maintenance of 3-plane correction and 0% non-union rate at 4 months following an immediate weight-bearing protocol with the Lapiplasty® Procedure.



Evidence-Based Bunion Surgery: A Critical Examination of Current and Emerging Concepts and Techniques

Dayton, Paul D. (Ed.).
Springer International Publishing [Textbook]. 2018.

Summary: This textbook provides a critical examination of the traditions and techniques commonly taught for bunion surgery and contrasts them with new, evidence-based anatomic and surgical concepts (including the Lapiplasty® Procedure).



Biomechanical Characteristics of Biplane Multiplanar Tension-Side Fixation for Lapidus Fusion

Dayton P, Hatch DJ, Santrock RD, Smith B.
J Foot Ankle Surg. 2018, 57:766-770.

Summary: Biomechanical study comparing the Lapiplasty® Plantar Python® tension-side fixation construct to Lapiplasty® Biplanar™ Plating, demonstrating a 17% improvement in maximum load to failure and a 103% increase in the cycles to failure (simulating post-operative weight-bearing).

Additional Lapiplasty® Publications

- Ray JJ, et al. Hallux Valgus. Foot and Ankle Orthopaedics. 2019, 4:1-12.
- Smith WB, et al. Understanding Frontal Plane Correction in Hallux Valgus Repair. Clin Podiatr Med Surg. 2018, 35:27-36.
- Feilmeier M, et al. Comparison of Transverse and Coronal Plane Stability at the First Tarsal-Metatarsal Joint With Multiple Screw Orientations. Foot Ankle Spec. 2017, 10:104-108.
- DeCarbo W, et al. Triplanar Correction for First Metatarsophalangeal Fusion. J Foot Ankle Surg. 2021, 60: 1044-1047.
- Dayton M, et al. What Do Patients Report Regarding Their Real-World Function Following Triplane Metatarsophalangeal Joint Arthrodesis for Hallux Valgus? J Foot Ankle Surg. 2022.
- McAleer JP, et al. A Systematic Approach to the Surgical Correction of Combined Hallux Valgus and Metatarsus Adductus Deformities. J Foot Ankle Surg. 2021, 60(5):1048-1053.
- Shah M, et al. Utilization of the Modified Lapidus Procedure. Foot Ankle Spec. 2022.
- Easley, M.A., Santrock RD. Lapiplasty: Three-Dimensional First Tarsometatarsal Arthrodesis for Hallux Valgus. Operative techniques in foot and ankle surgery 3rd Edition. Copyright © 2022 Wolters Kluwer.
- Smith WB, Santrock RD, Hatch DJ, Dayton P. Multiplanar Alignment System to Guide Triplanar Correction of Hallux Valgus Deformity. Techniques in Foot & Ankle Surgery. 2017, 16:175-82.

The Evidence-Based Triplanar Solution Backed by 21 Peer-Reviewed Lapiplasty® Publications

Lapiplasty® offers:	
97-99% reproducible 3D correction (as demonstrated in 13 & 17 month studies) ^{1,2}	✓
<2 weeks to return to weight-bearing in a boot ^{1,5}	✓
10.4mm average reduction in foot width ³	✓
2.4-3.1mm average shortening of first ray ⁴	✓
2-3% non-union rate (9.5 & 13.5 month follow-up) ^{1,5}	✓
3% hardware removal rate (in a 13 month study) ⁵	✓
1-3% recurrence rate (as demonstrated in 13 month studies) ^{1,2}	✓
30% increase in cycles to failure with Biplanar™ Plating ⁶ (compared to dorsomedial Lapidus plate + compression screw)	✓
>80% reduction in pain levels per VAS and MOxFQ scoring systems (interim analysis from ALIGN3D™ study of 40 patients at 24 months) ⁷	✓

Learn more about our **21 peer-reviewed publications** at treace.com



©2022 Treace Medical Concepts, Inc. All rights reserved. Pat. www.treace.com/patents M646E

1 Ray J, et al. Foot Ankle Int. 2019;40(8):955-960. | 2 Dayton P, et al. J Foot Ankle Surg. 2020, 59(2): 291-297. | 3 Vaida J, et al. Foot & Ankle Orthopaedics 2020 Aug; 5(3) 1-5
4 Hatch D, et al. Foot & Ankle Orthopaedics 2020, 5(4): 1-8. | 5 Dayton P, et al. J Foot Ankle Surg. 2019; 58(3):427-433. | 6 Dayton P, et al. J Foot Ankle Surg. 2016. 55:567-71.
7. Liu, G.T. et al. J Foot Ankle Surg. 2022 Apr 26