

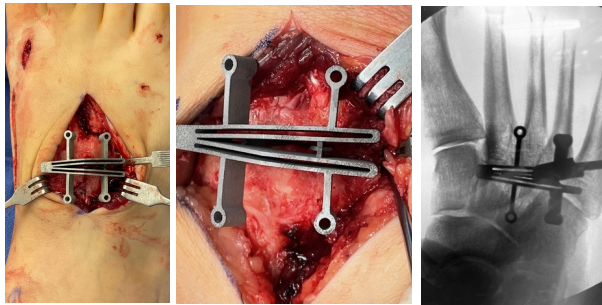


Interim 1-Year Analysis of a Multicenter Prospective Study Assessing Radiographic and Patient Outcomes Following Combined Metatarsus Adductus and Hallux Valgus Correction with Early Weightbearing

Statement of Purpose

This study evaluated the clinical, radiographic, and patient-reported outcomes in patients undergoing instrumented 3-2-1 tarsometatarsal (TMT) arthrodesis for correction of combined hallux valgus and metatarsus adductus (MTA) deformities.

Figure 1 | Clinical (left) and radiographic (right) image of the cut guide utilized to correct the MTA deformity. A continuous closing wedge cut is made across the 2nd and 3rd TMT joints with the apex at the medial aspect of the 2nd TMT joint.



Introduction

MTA is a complicating factor in 29% of HV patients and poses significant issues for under-correction and recurrence of HV if not addressed.¹ A reliable and reproducible method is needed to provide anatomic correction of the midfoot deformity so that the first ray alignment can be normalized. To date there are few studies proposing a reliable method for correction. We are using an instrumented technique to realign the second through fifth rays setting the stage for complete triplane correction of the first ray.

Methods

This is an interim analysis of a prospective multicenter study on patients with symptomatic HV and MTA treated utilizing cut guides for angular correction arthrodesis of the 2nd and 3rd TMT and 1st ray correction at the 1st TMT. Titanium 4-hole locking plates were utilized for fixation at each joint. Patients were allowed to weight bear in a CAM boot within two weeks. Outcomes included radiographic correction of HV and MTA deformities, patient-reported outcomes (VAS, MOxFQ, and PROMIS-29), and clinical complications. The metatarsus adductus angle (MAA) was measured using the traditional Sgarlato's method, and True IMA was calculated as $IMA + MAA - 15$.²

Results

Results Sixty eligible patients (mean [range] age: 41.2 [14-77] years) underwent HV and MTA correction, of whom 33 completed 12-month visits. Mean (95% CI) time to protected weightbearing and return to full unrestricted activity were 7.9 (5.5, 10.2) days and 3.8 (3.6, 4.0) months, respectively. Clinically significant improvements from baseline in HVA, IMA, TSP, MAA angle, True IMA, and osseous foot width were maintained through 12 months. Improvements in patient-reported outcomes were maintained through 12 months for VAS, MOxFQ, and PROMIS-29. There were no complications that required subsequent surgery.

Conclusions

These interim results of this 5-year prospective, multicenter study of an instrumented approach to HV and MTA correction via 3-2-1 TMT arthrodesis with early weightbearing demonstrated favorable radiographic correction of the HV and MTA deformities, positive patient-reported outcomes, and a low rate of clinical complications.

- Early return to weight-bearing in a CAM boot (mean 7.9 days).
- Maintenance of HV (IMA, HVA, TSP) and MTA (MAA, True IMA) radiographic correction through 12 months.
- Clinically significant reduction in pain (VAS) and patient reported outcomes (MOxFAQ, PROMIS-29) through 12 months.

Figure 2 | Representative preoperative (left) and 12-month postoperative (right) radiographs.

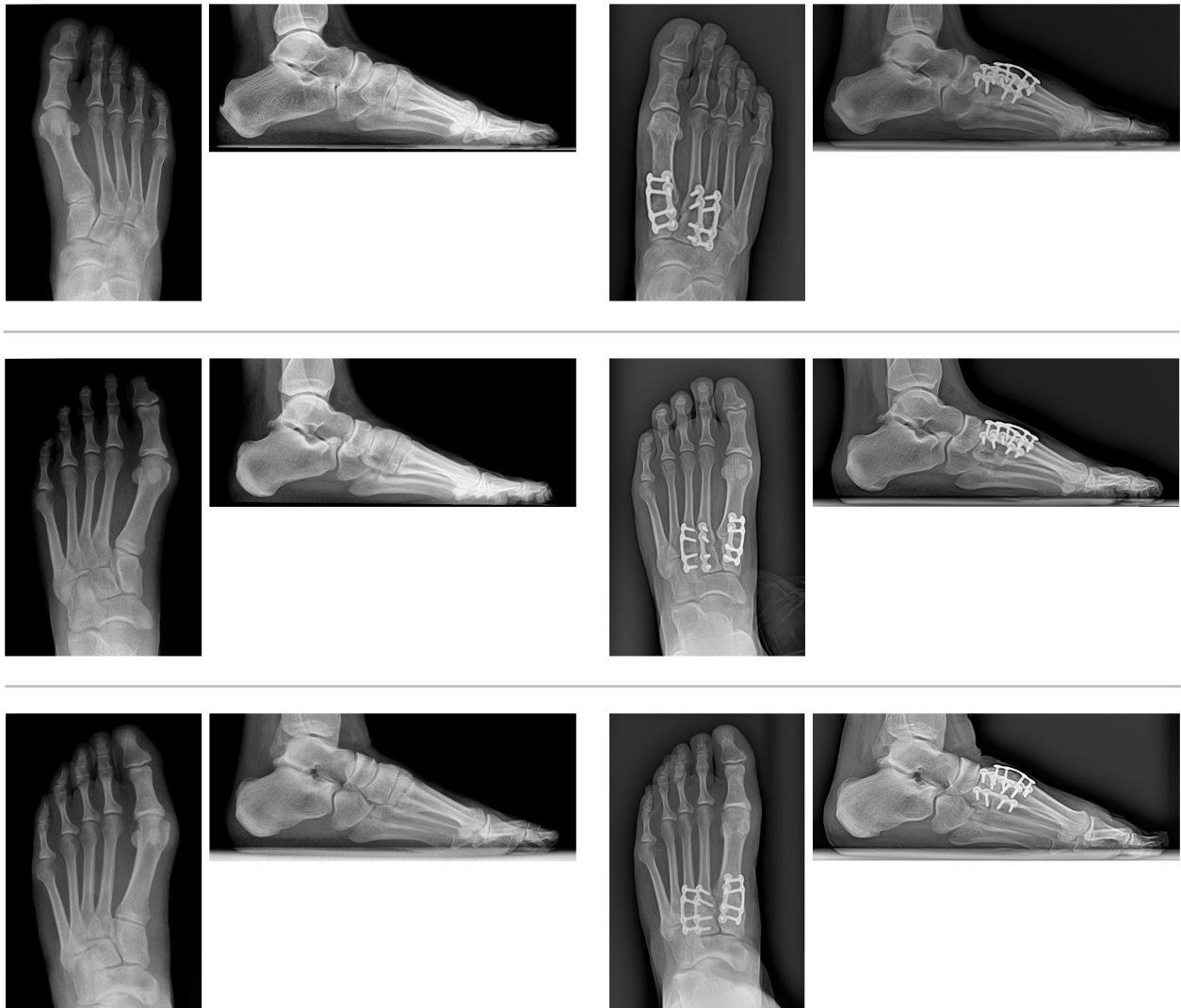


Table 1 | Patient Demographics
 The interim results of 60 patients with **mean (SD) follow-up of 11.6 (8.2) months***.

Baseline Characteristics	Category	Value
Age (yrs), Mean (SD)		41.2 (16.0)
Sex, n(%)	Female	54 (90.0%)
	Male	6 (10.0%)
BMI, Mean (SD)		29.0 (5.2)
Index Foot	Left	34 (56.7%)
	Right	26 (43.3%)

*Follow-up is duration of time from date of index procedure to date of latest post-procedure visit.

Table 2 | Return to Weightbearing
 Patients underwent an **early weightbearing** protocol.

Post-Operative Time to Return to Activity/Work	
Activity	Mean (95% Confidence Interval)
Weightbearing in CAM boot (days, n=57)	7.9 (5.5, 10.2)
Return to work (days, n=52)	34.0 (26.5, 41.5)
Return to shoes (weeks, n=53)	8.4 (5.9, 10.9)
Return to unrestricted activity (months, n=43)	3.8 (3.6, 4.0)

Table 3 | Radiographic Measures, mean (95% confidence interval)

Clinically significant **improvement over baseline in radiographic measures (HVA, IMA, TSP, MAA, True IMA, and Osseous Foot Width)** through 12 month post-op.

Radiographic Measure	Baseline (n=56)	6 Week (n=52)	6 Month (n=40)	12 Month (n=31)
Hallux Valgus Angle (HVA)	29.3° (27.0, 31.6)	8.5° (6.8, 10.1)	8.6° (6.2, 11.1)	8.9° (6.3, 11.5)
Intermetatarsal Angle (IMA)	12.4° (11.6, 13.1)	4.9° (4.0, 5.7)	5.5° (4.7, 6.4)	5.8° (5.0, 6.7)
Tibial Sesamoid Position (TSP)	4.6 (4.3, 4.9)	2.1 (1.8, 2.4)	2.5 (2.1, 2.9)	2.5 (2.1, 2.9)
Metatarsus Adductus (MAA)	19.5° (17.8, 21.1)	9.1° (8.0, 10.1)	9.5° (8.1, 10.8)	9.6° (8.0, 11.3)
True IMA	16.9° (15.2, 18.5)	-1.1° (-2.4, 0.2)	0.0° (-1.6, 1.5)	0.5° (1.3, 2.3)
Osseous Foot Width (mm)	94.3 (92.5, 96.1)	83.7 (81.8, 85.6)	86.9 (84.8, 89.0)	86.2 (83.2, 89.2)

Table 4 | Patient Reported Outcomes, mean (95% confidence interval)

Clinically significant improvement over baseline in VAS, MOxFQ, and PROMIS-29 through 12 months post-op.

Measure	Baseline (n=60)	6 Week (n=56)	6 Month (n=46)	12 Month (n=33)
VAS Pain Score	4.1 (3.6, 4.6)	1.7 (1.4, 2.1)	1.9 (1.4, 2.3)	1.1 (0.7, 1.6)
Measure	Baseline (n=60)	6 Month (n=47)	12 Month (n=33)	
MOxFQ (Social Interaction)	38.0 (32.5, 43.5)	13.6 (8.6, 18.5)	10.8 (4.0, 17.6)	
MOxFQ (Walk/Stand)	43.6 (37.6, 49.6)	23.6 (17.2, 30.1)	16.1 (8.8, 23.5)	
MOxFQ (Pain)	54.8 (49.5, 60.0)	27.7 (21.6, 33.7)	23.3 (16.2, 30.4)	
MOxFQ (Index Score)	45.7 (40.7, 50.7)	22.4 (16.8, 27.9)	17.0 (10.3, 23.8)	
Measure	Baseline (n=53)	6 Month (n=45)	12 Month (n=32)	
PROMIS-29 (Adult) (Ability to Participate in Social Roles/ Activities)	54.6 (52.3, 56.8)	58.7 (56.5, 60.9)	58.5 (56.0, 61.1)	
PROMIS-29 (Adult) (Pain Interference)	54.0 (51.8, 56.1)	48.3 (45.8, 50.7)	46.9 (44.4, 49.4)	
PROMIS-29 (Adult) (Physical Function)	45.9 (43.5, 48.3)	50.8 (48.6, 52.9)	53.0 (50.8, 55.1)	

An increase from baseline in Ability to Participate in Social Roles/Activities and Physical Function indicates improvement.

A decrease from baseline in Pain Interference indicates improvement.

Table 5 | Clinical Complications - presented at the patient level**A total of 4 adverse events (AEs) were reported, 2 hardware failures, and one non-union;** none of which required surgical intervention.

Not Requiring Surgical Intervention	Number (%) (n=60)
Hardware failure, hardware not removed	2 (3.3%)
Pain	2 (3.3%)
Infection	1 (1.7%)
Wound Complication	1 (1.7%)
Non-union at 12 months*	1 (3.0%)
Hardware removal per patient request	1 (1.7%)

*Non-union defined as pain and lucency at the 1st, 2nd, and/or 3rd TMT joint at 12 months post Adductoplasty® and Lapiplasty® Procedure

References

1. Aiyer et al, FAI 2016; 37 (165-171)
2. Sgarlato TE, Compendium of Podiatric Biomechanics Vol 1971; Chapter 5



www.treace.com

©2025 Treace Medical Concepts, Inc. All rights reserved. Pat. treace.com/patents M3972A